

Skříčkový seminář:

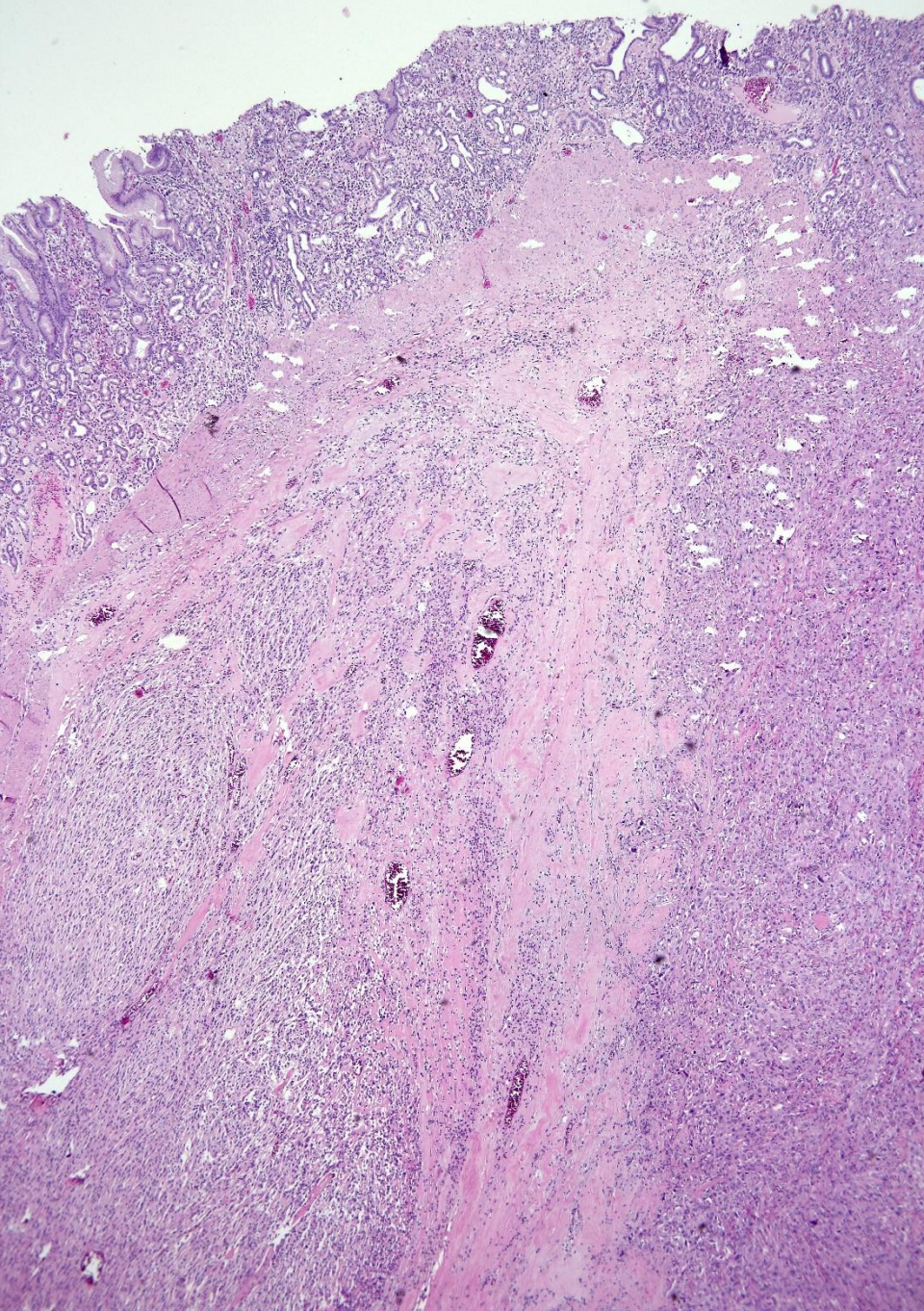
případ č. 6 (SD-IAP č. 723)

Ondřej Daum

Plzeň, ČR



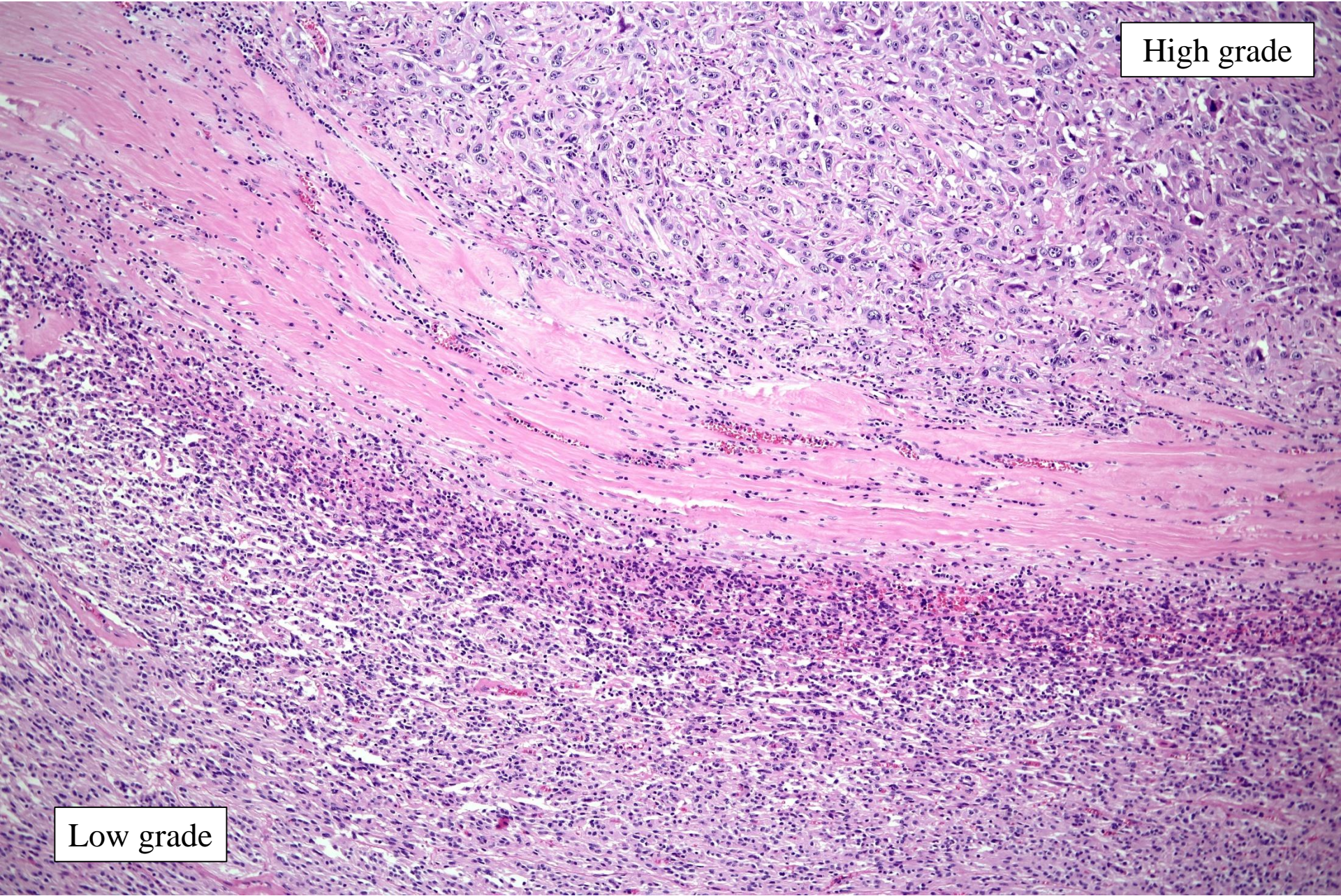
Nie som v konflikte záujmov vo vzťahu k vyššie uvedenej vzdelávacej aktivite a jej organizátorovi

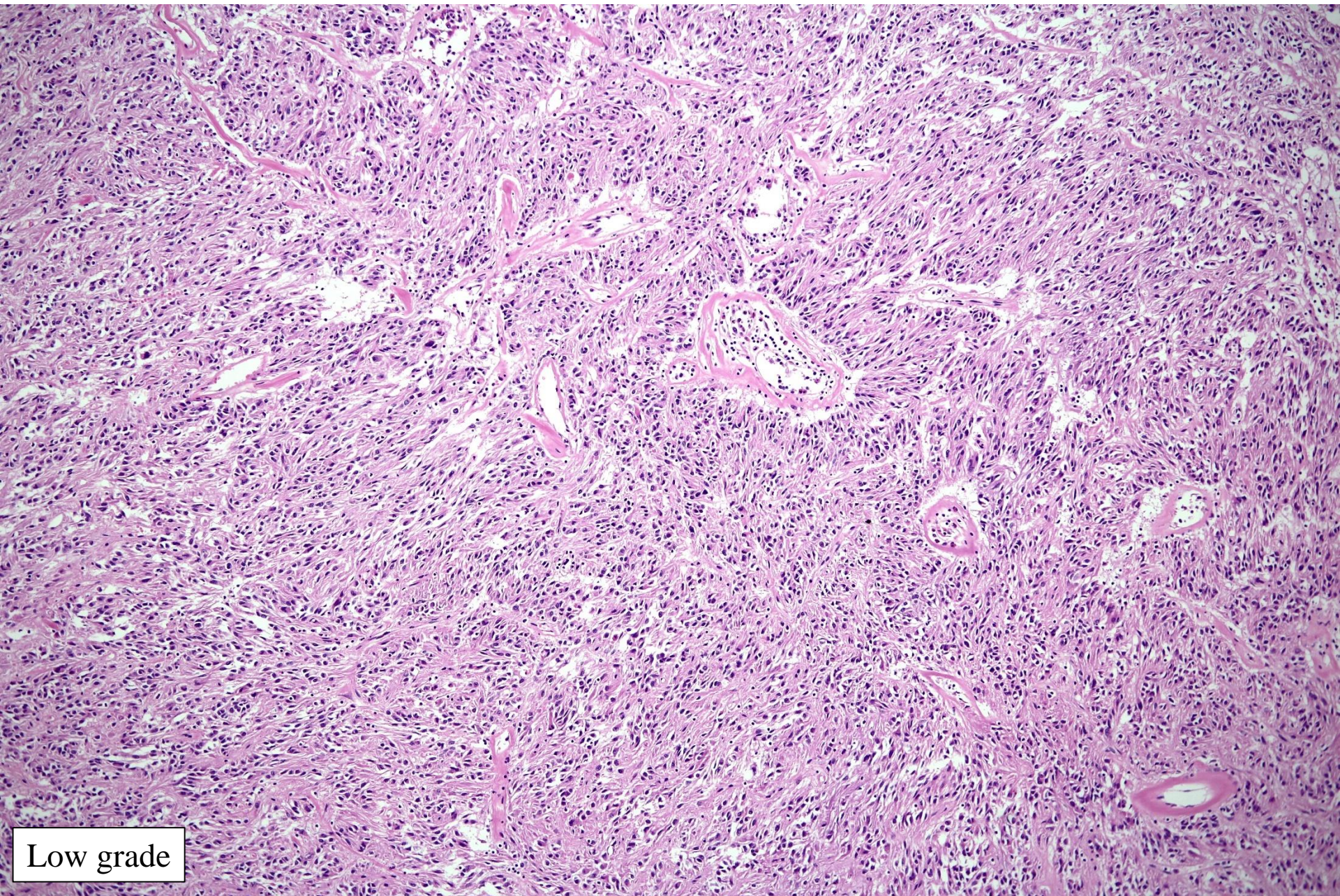


- Žena, 48 let.
- Exulcerovaný nádor žaludku
 - maximální rozměr 6 cm
 - prorůstá stěnou až do subserózy
 - v 5 z 11 zastižených lymfatických uzlin metastázy téhož nádoru
 - omentum bez nádorových struktur

High grade

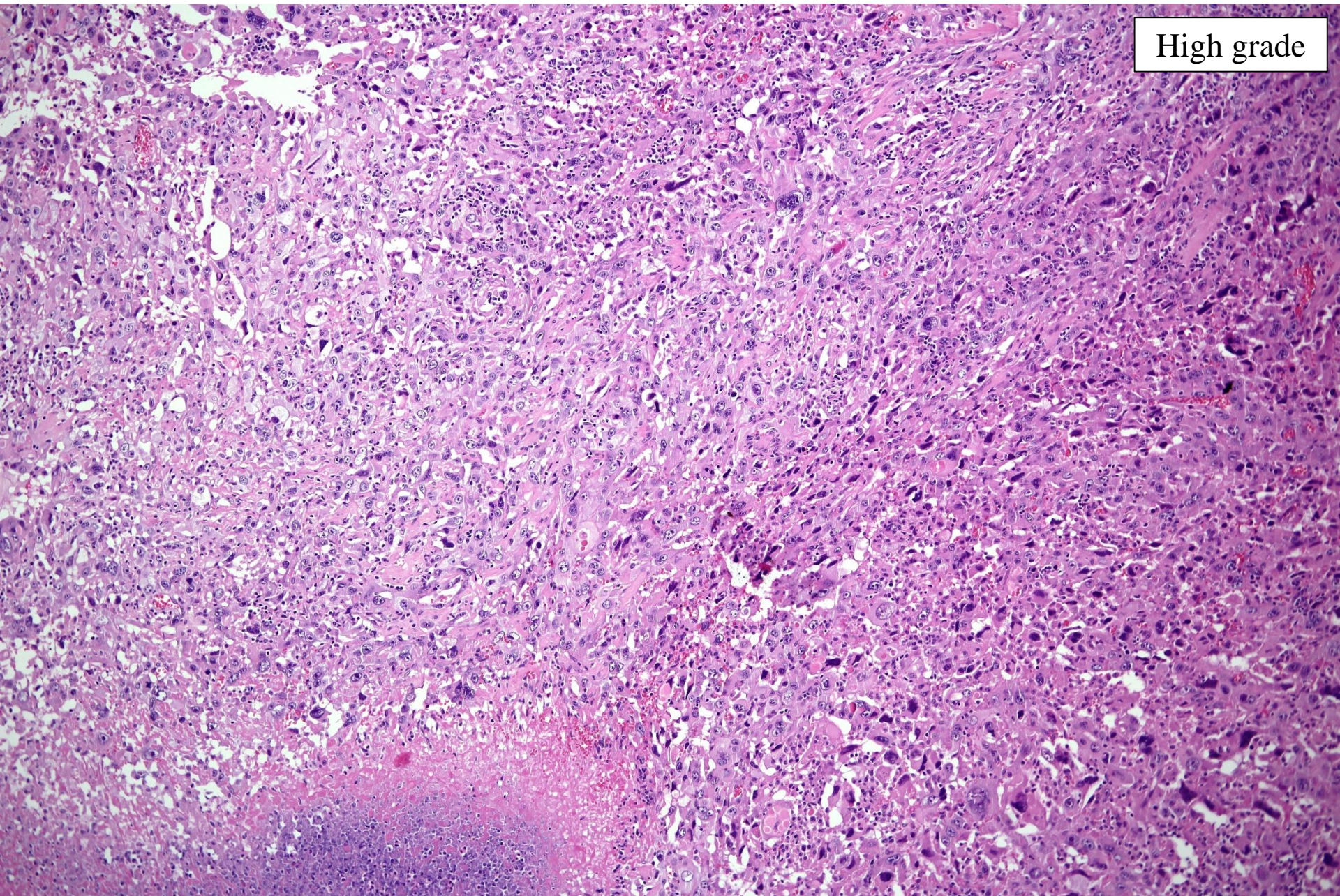
Low grade

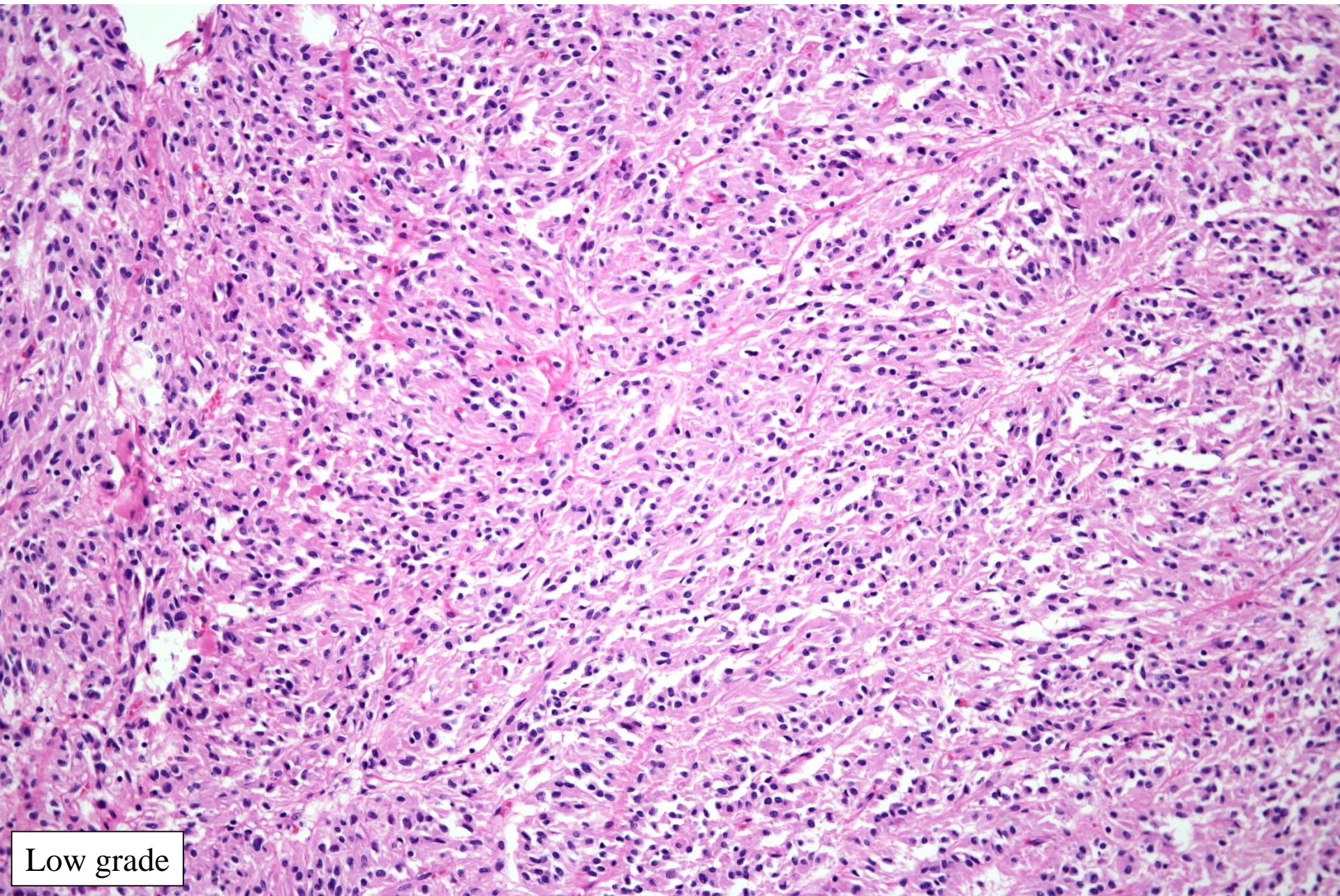




Low grade

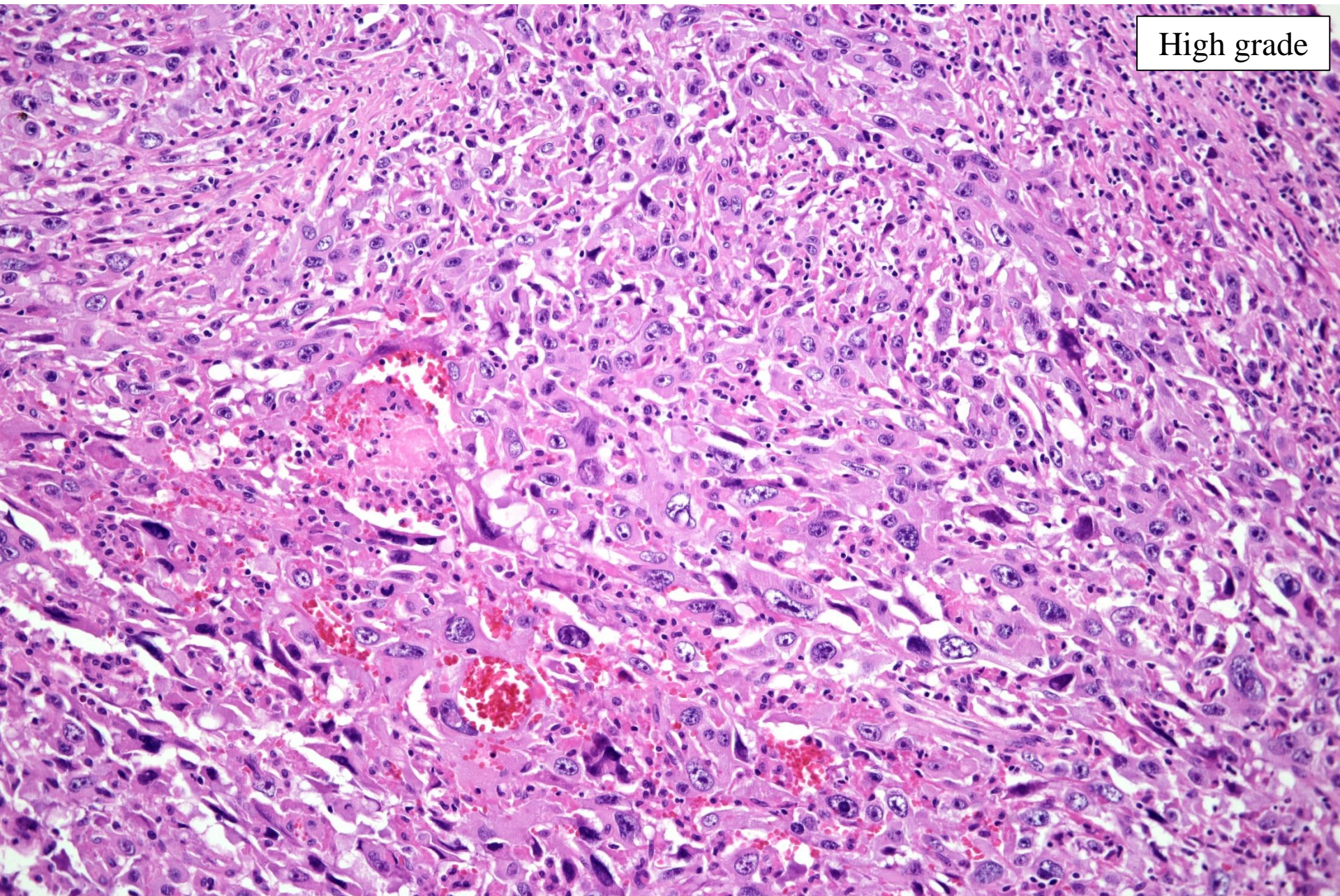
High grade

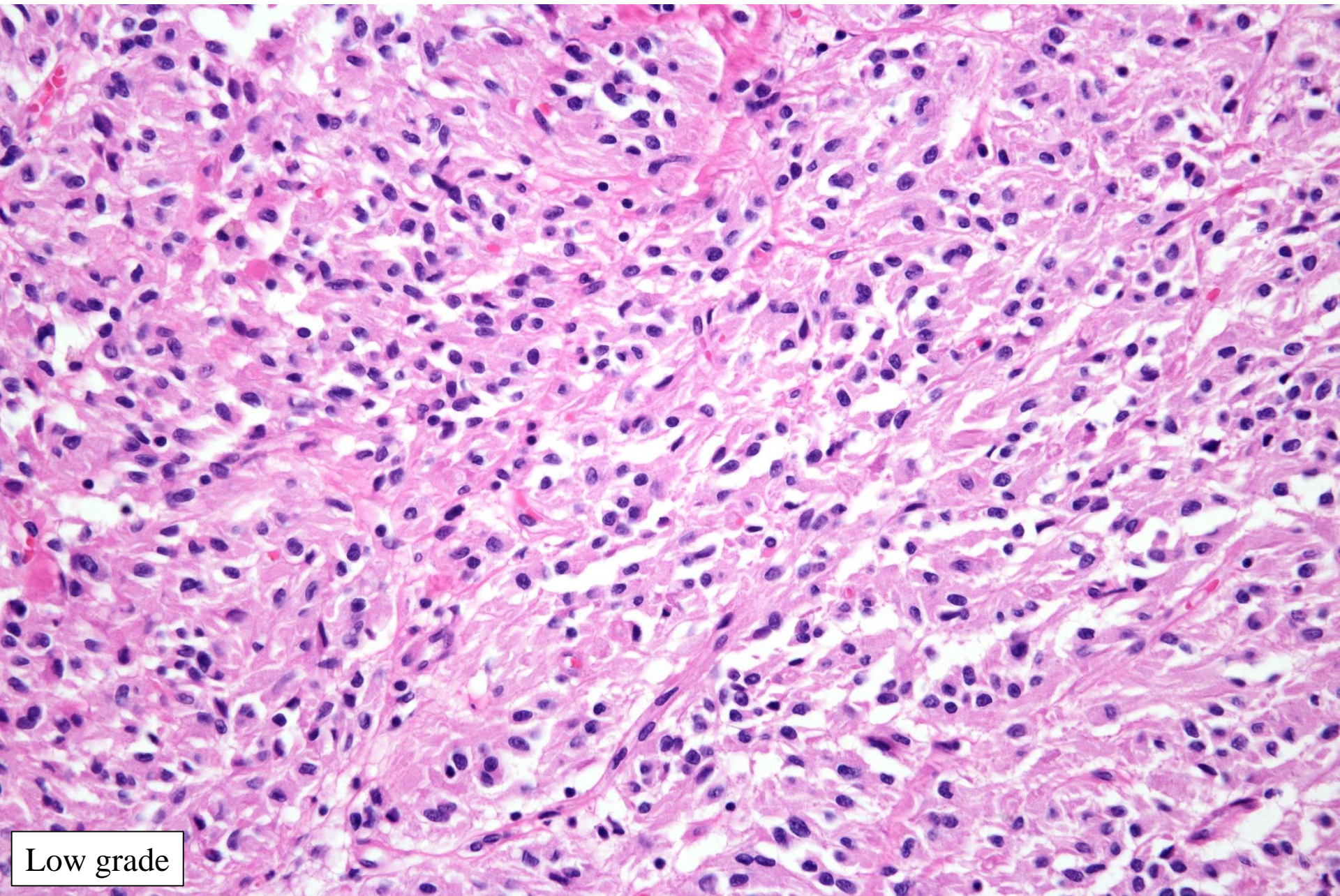




Low grade

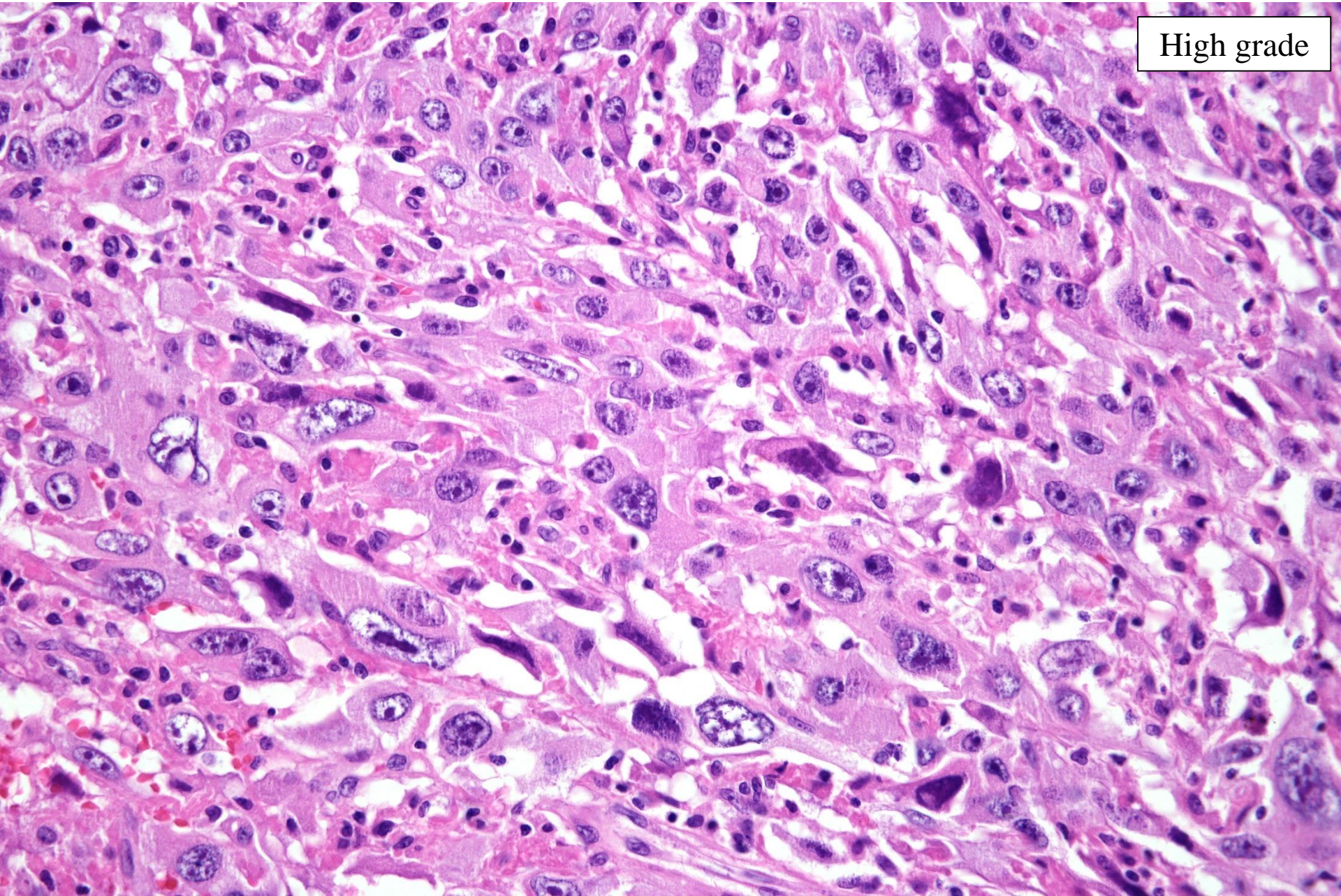
High grade



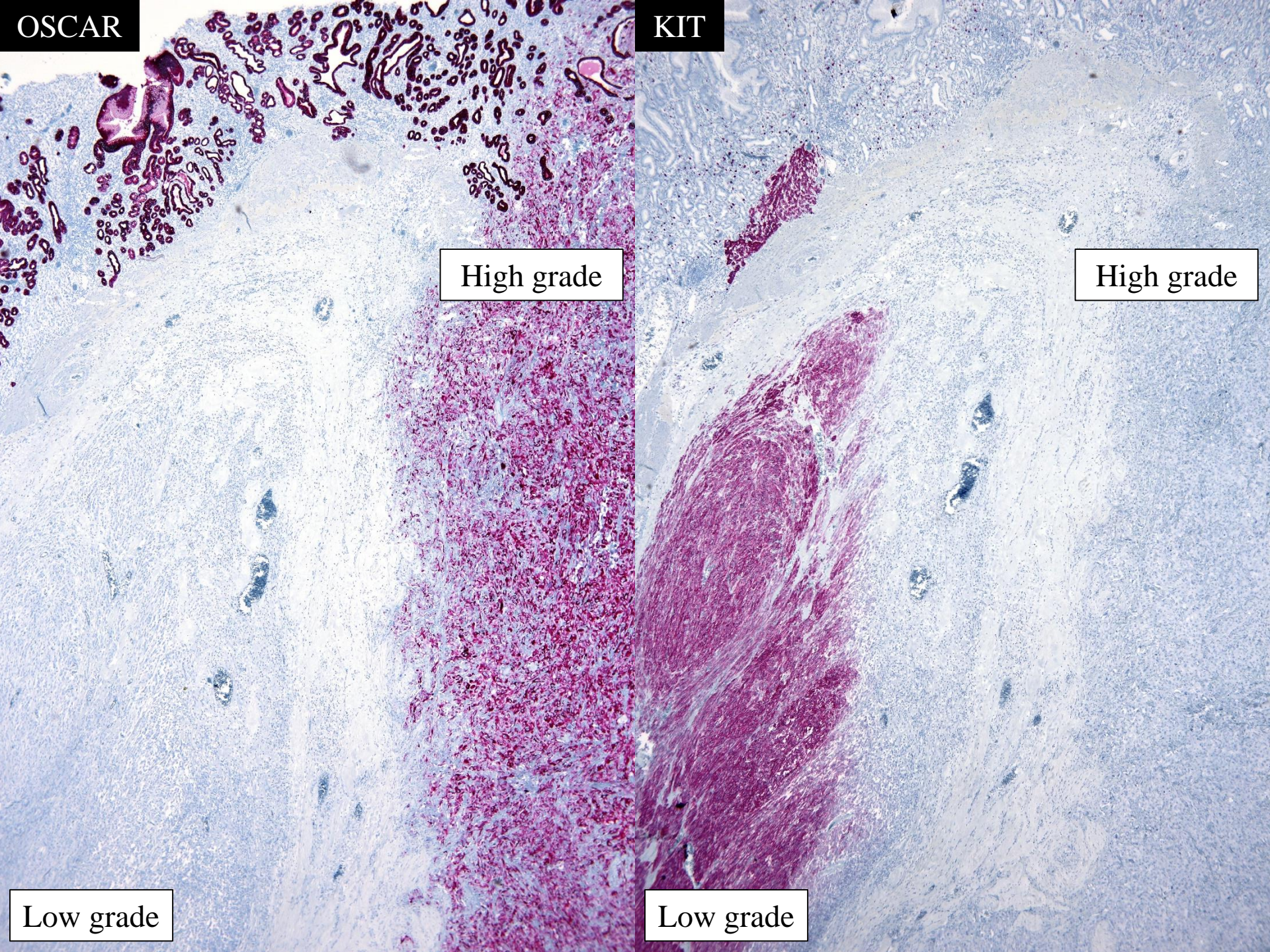


Low grade

High grade







OSCAR

KIT

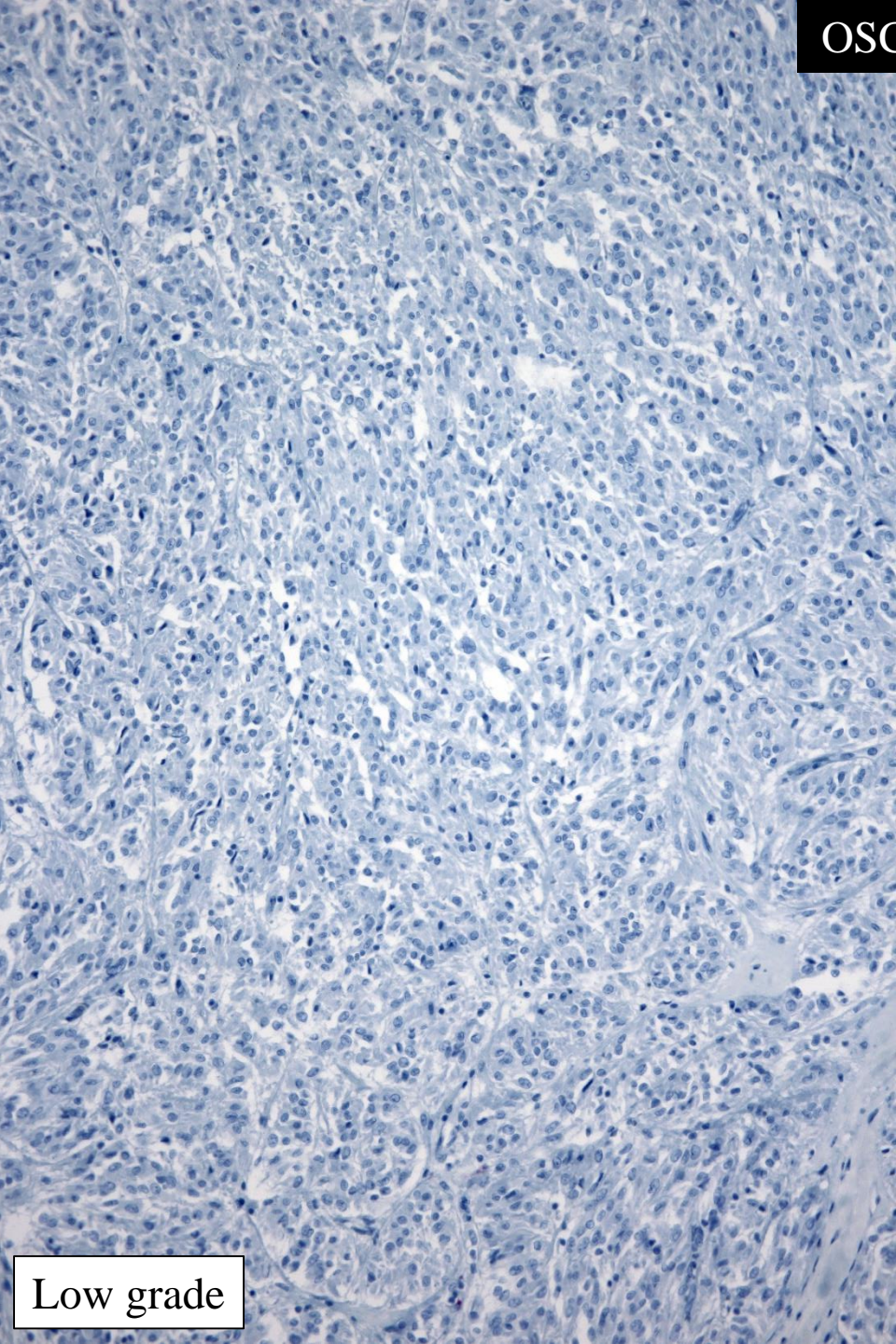
High grade

High grade

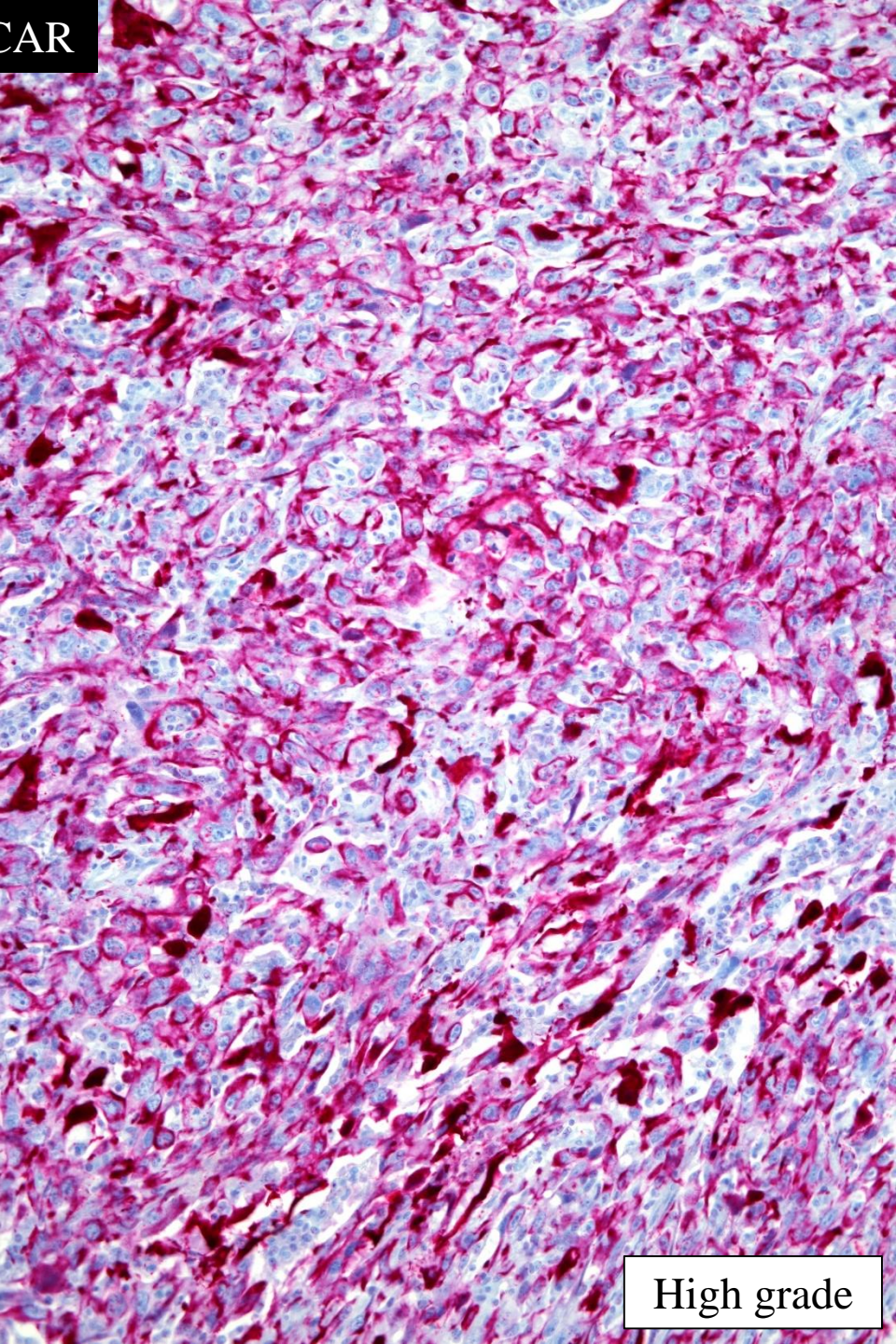
Low grade

Low grade

OSCAR

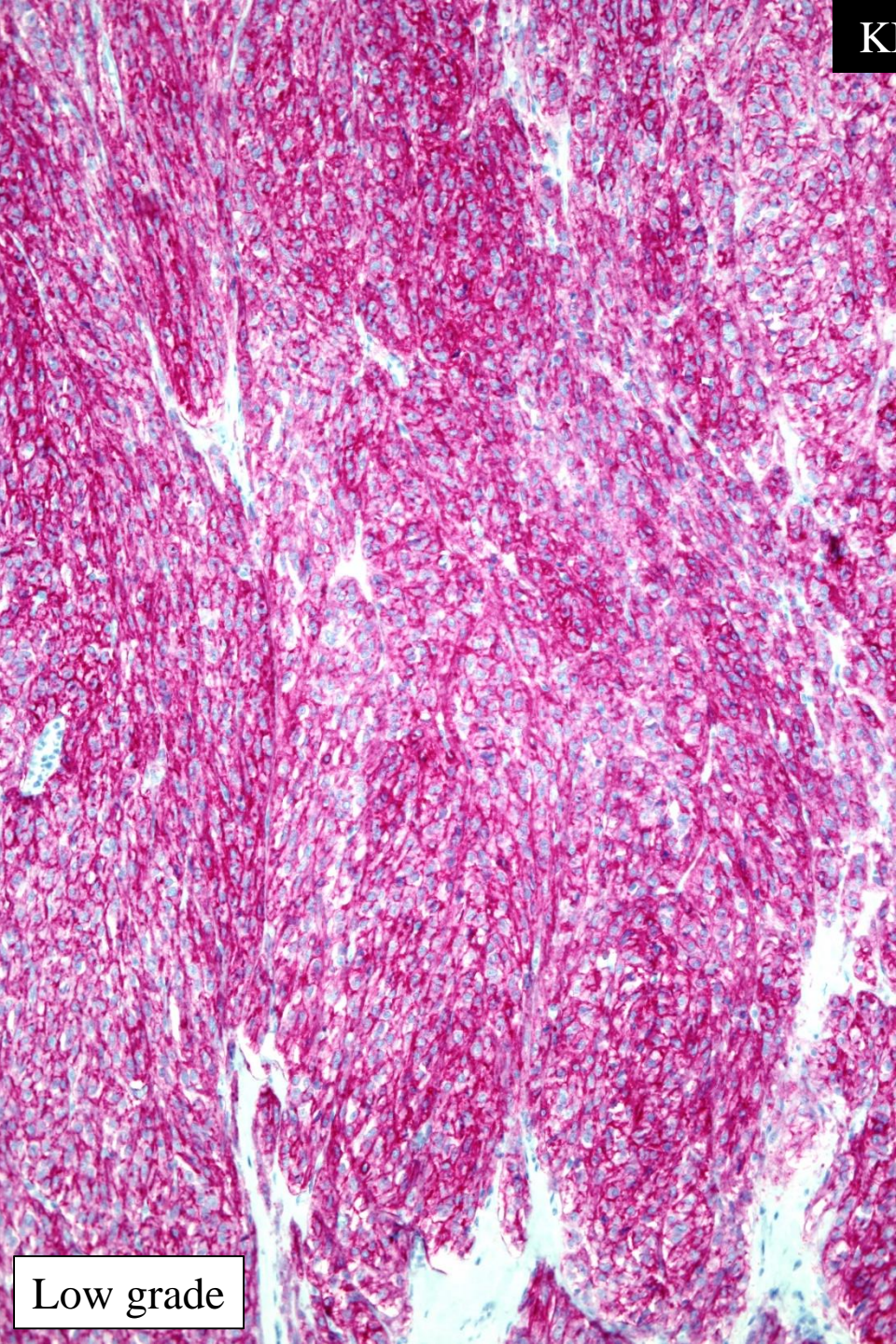


Low grade

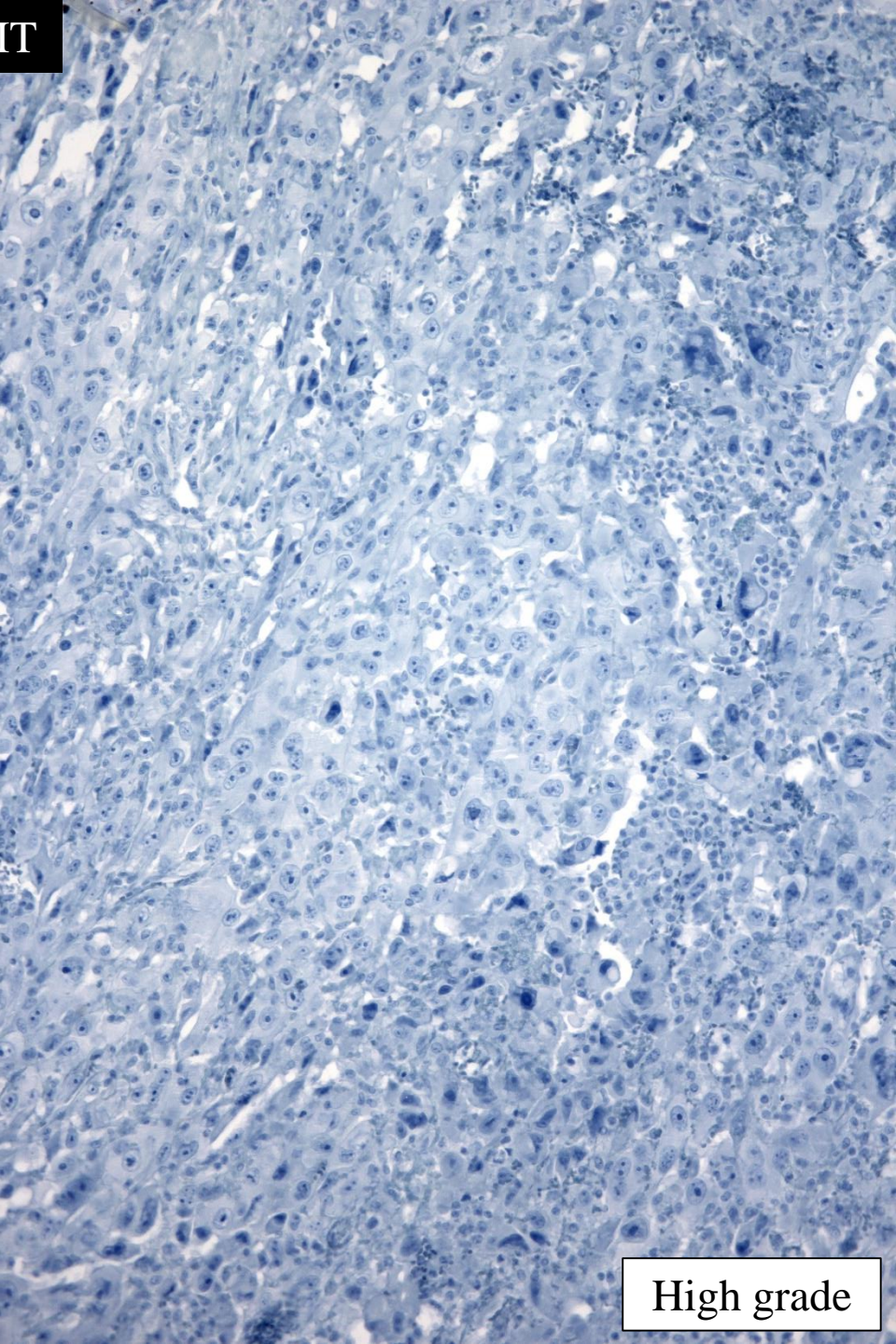


High grade

KIT



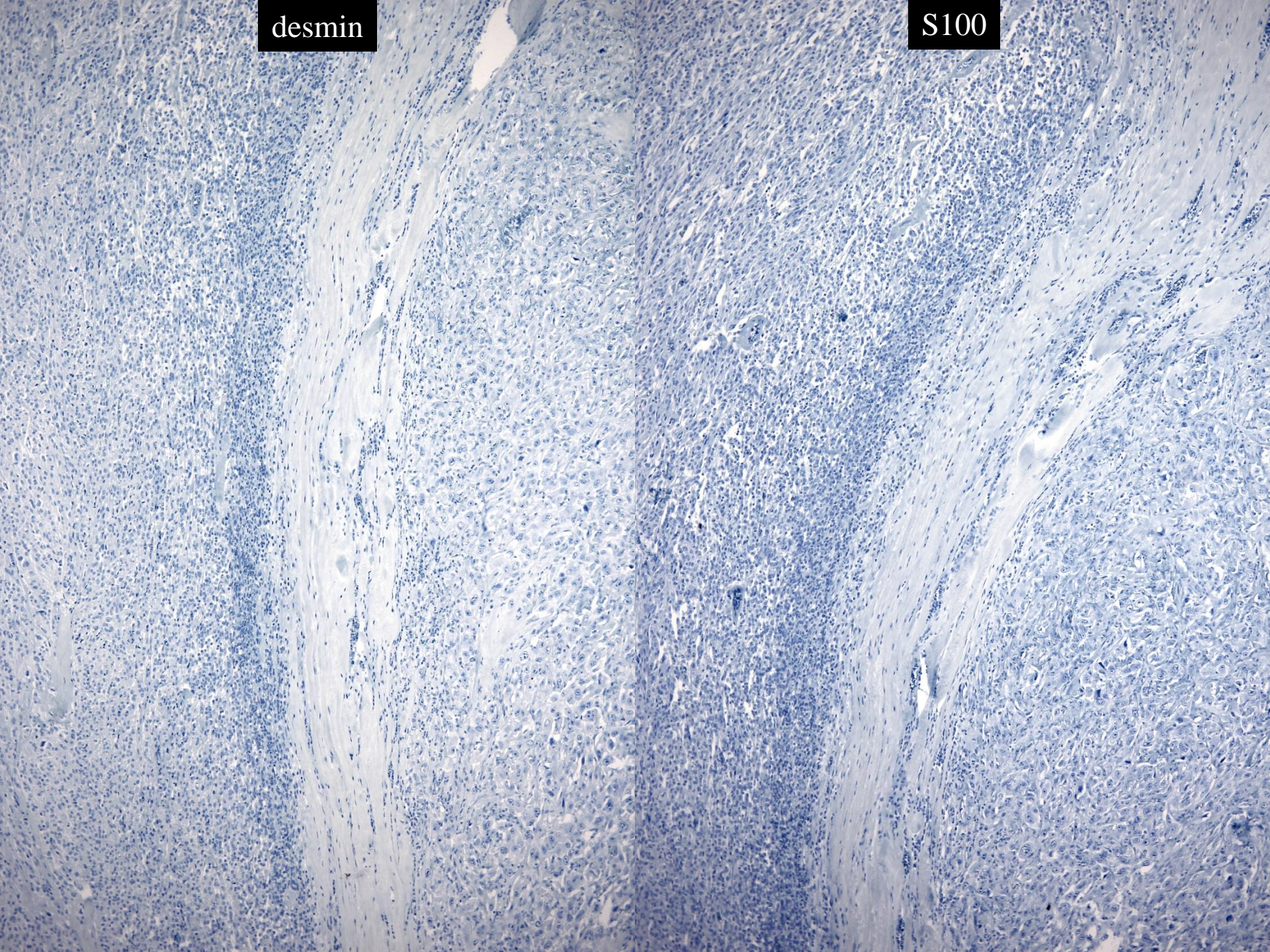
Low grade



High grade

desmin

S100



Histopathology, 2002 May;40(5):480-1.

Cytokeratin expression in gastrointestinal stromal tumours: a word of caution.

Nga ME¹, Wong AS, Wee A, Salto-Tellez M.

Histopathology, 2004 Jan;44(1):77-80.

CD117 expression in oesophageal carcinosarcoma: a potential diagnostic pitfall.

Martland GT¹, Goodman AJ, Shepherd NA.

CASE REPORT

The value of c-kit mutational analysis in a cytokeratin positive gastrointestinal stromal tumour

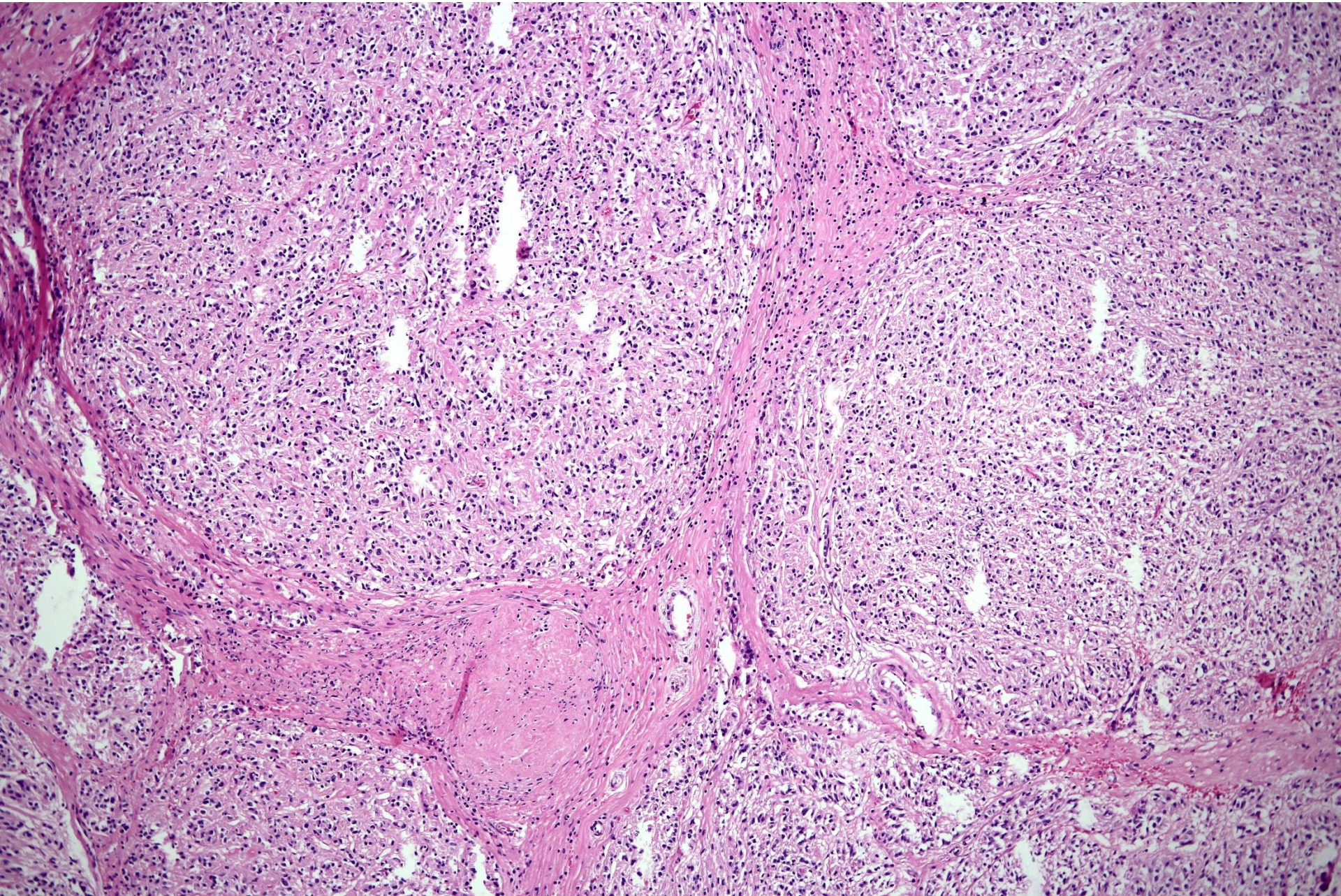
G Rossi, G Sartori, R Valli, F Bertolini, N Bigiani, L Schirosi, A Cavazza, G Luppi

.....
J Clin Pathol 2005;58:991-993. doi: 10.1136/jcp.2004.024364

- 1) dediferencovaný GIST (high-grade komponenta představuje populaci buněk s aberantní DOG1- CD117- CK+).
- 2) sarkomatoidní karcinom (aberantním jevem ztráta DOG1+ CD117+ a CK-).
- 3) kolizi dvou nezávislých nádorů
- 4) něco úplně jiného

TLE-1 -
napsin A +

TTF1 -

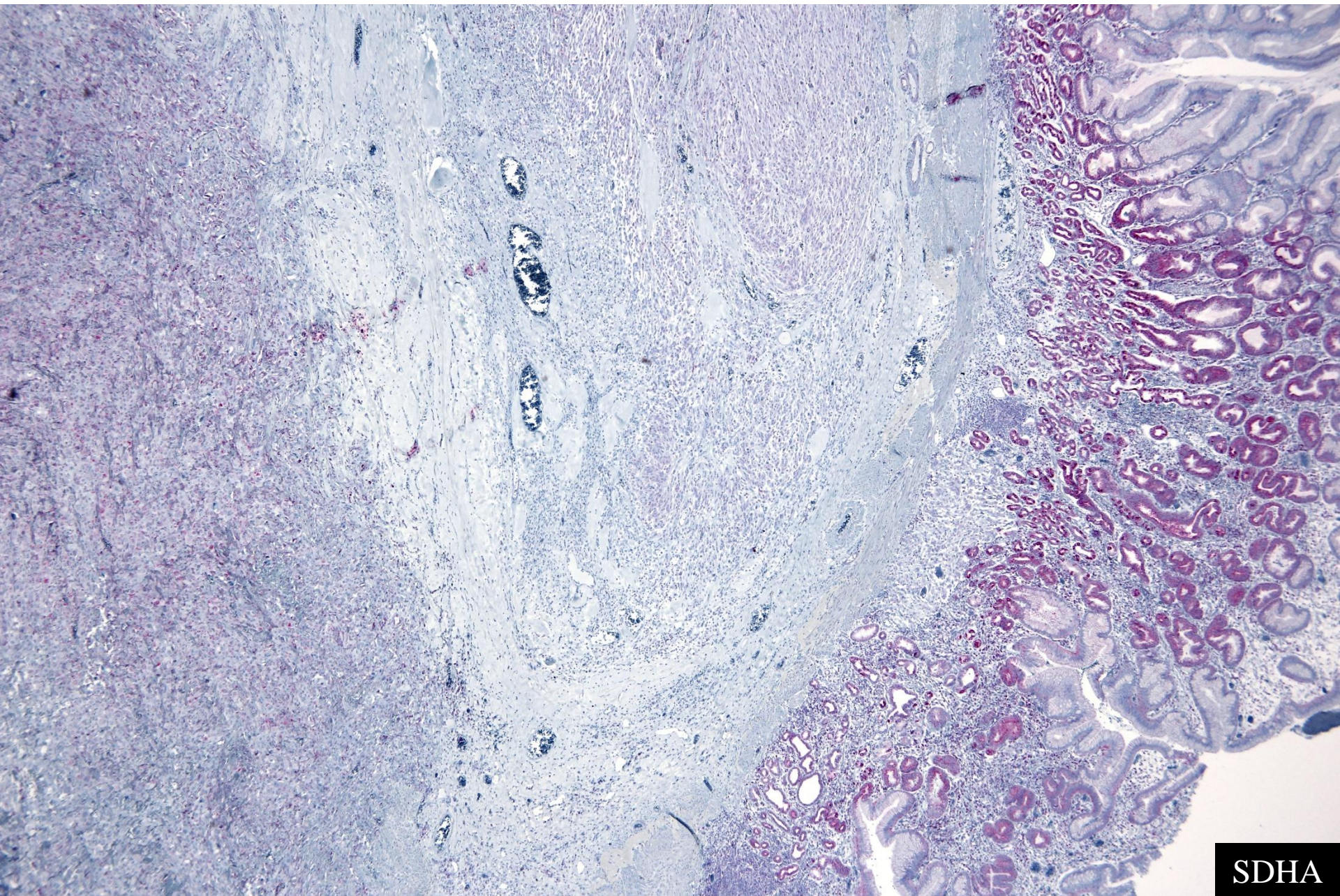


KIT wt

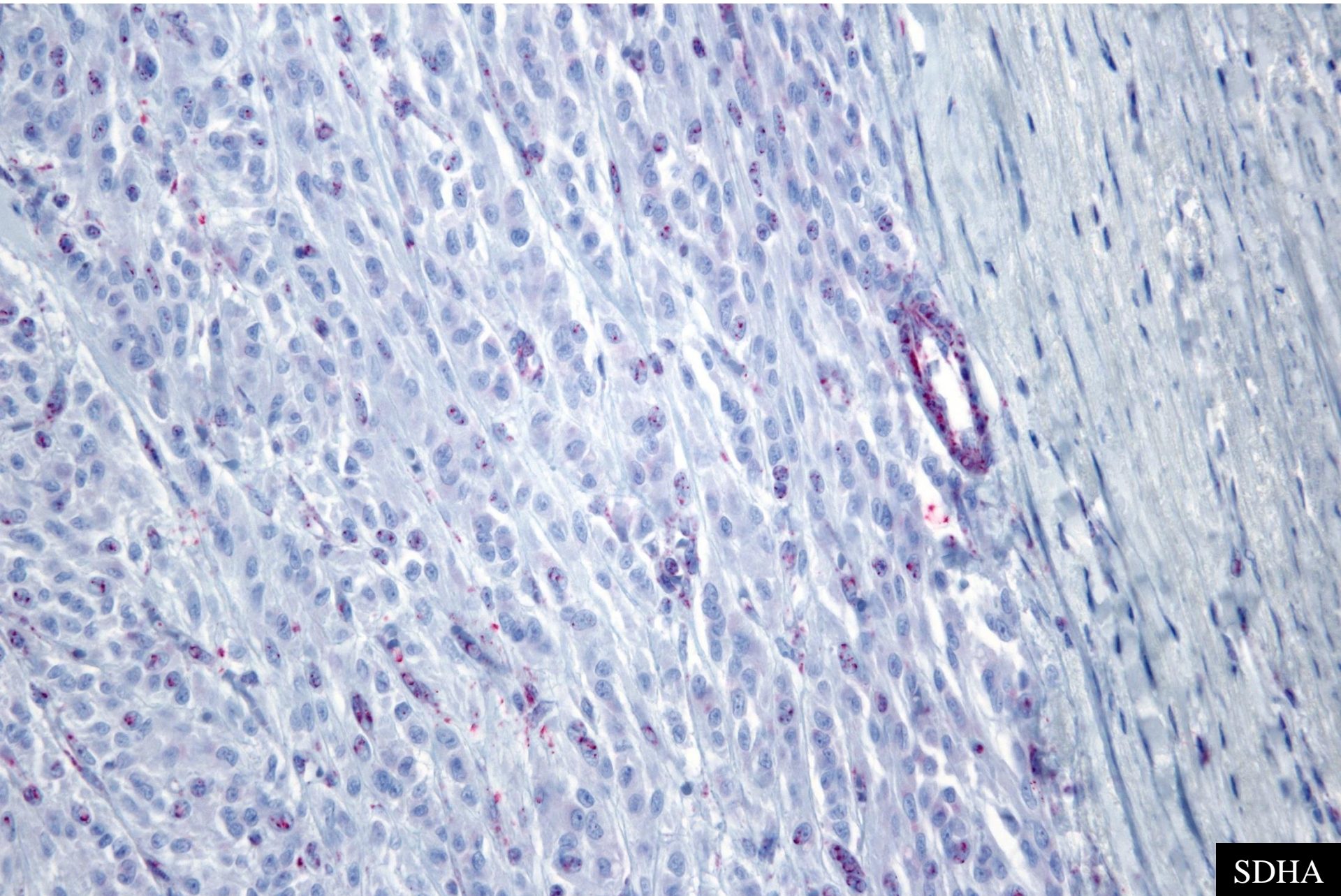
PDGFRA wt

SDHB-SDHD wt

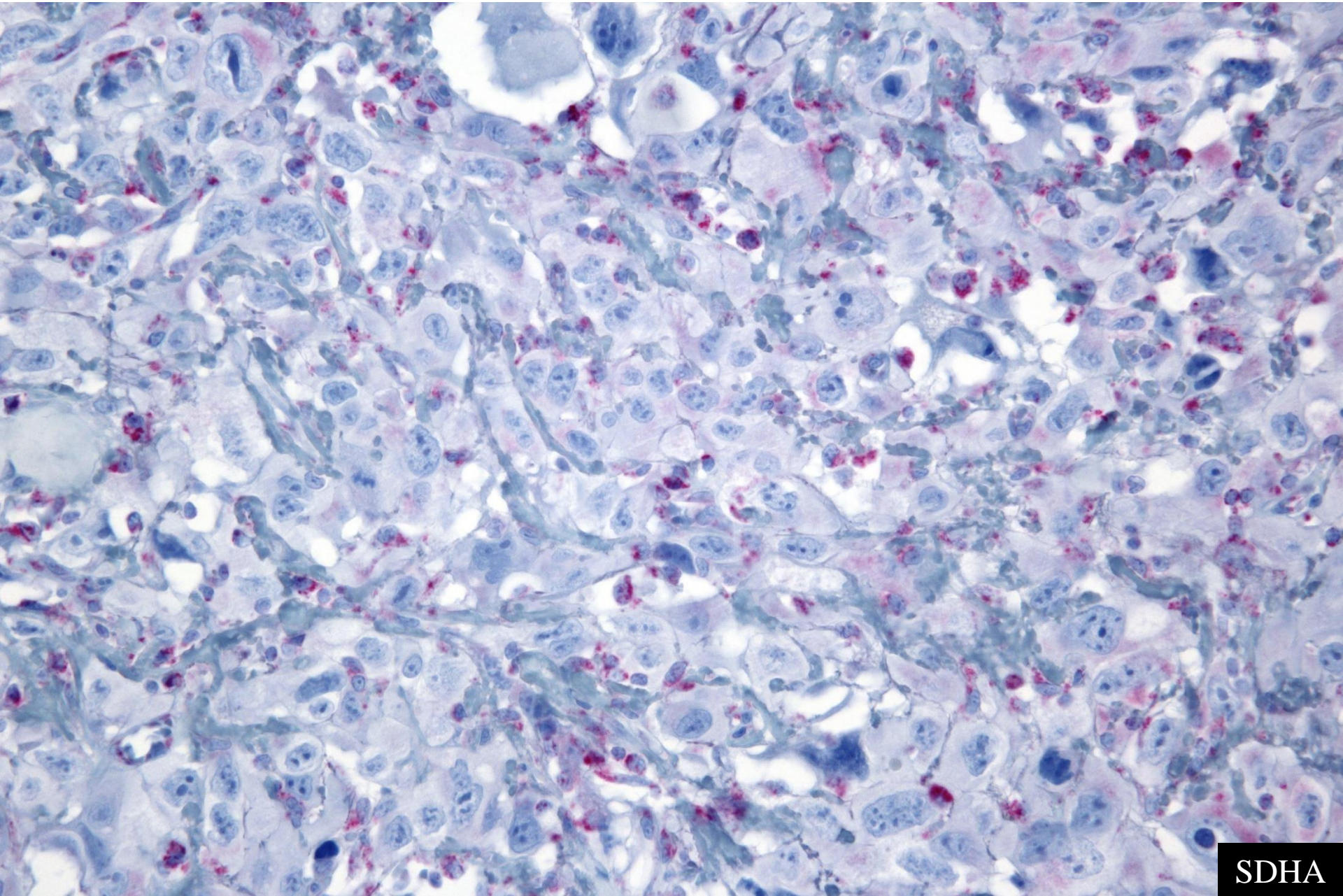
met*SDHC* -



SDHA



SDHA



SDHA

Ne zcela finální diagnóza:

Dediferencovaný *SDHA* mut GIST